E-ISSN 0976-2892

Efficacy of Corneal Collagen Crosslinking with Riboflavin and Ultraviolet A in Progressive Keratoconus

Delhi J Ophthalmol 2013; 24 (1): 23-27
DOI: http://dx.doi.org/10.7869/djo.2013.4

Aneeta Jabbar,
***Seema KM**

Little Flower Hospital
Angamaly, Cochin, India

**Address for correspondence*

Seema KM *DO, DNB*

Cornea Consultant,
Little Flower Hospital
Angamaly, Cochin, India
email id: seemakm123@gmail.com

Purpose: *To analyze the efficacy of Corneal Collagen Crosslinking with Riboflavin and Ultraviolet- A in progressive Keratoconus.*

Materials and Methods: *Nonrandomized, interventional, prospective trial of 52 eyes of 45 patients, with progressive Keratoconus. The study was conducted between January 2009 and June 2011. Inclusion Criteria were documented progression of keratoconus by refraction, keratometry or topography with pachymetry more than 400 microns and age less than 35 years. Crosslinking was performed using Riboflavin 0.1% and ultraviolet-A light of 370nm using a 3mW/cm2 irradiance after removing the central 7mm of the corneal epithelium using a blunt knife. A bandage contact lens was fitted until reepithelialisation. Eyes with mild –moderate disease were included in category 1 and advanced to severe disease ware included in category 2.*

Results: *At 1 year an improvement in BCVA was seen in 42.31% in category 1 and in 26.92% of category 2. BCVA worsened in 11.54% of category 1 and 12.69% of category 2 and remained stable in rest. An improvement in the max K reading was seen in 32% of category 1 and in 36.36% of category 2. A one way ANOVA proves the means of the max K values before and after the procedure do not differ significantly. Spherical equivalent was also stable in both the groups at 1 year. A comparison of results between eyes with and without Vogts striae did not show statistically significant difference. Thus Crosslinking has shown some initial improvements in BCVA, refraction and keratometry , but results are not dramatic. The main effect is stabilisation of the ectasia.*

Keywords : *keratoconus • crosslinking • riboflavin • ultraviolet a • spherical equivalent*

Introduction

Corneal collagen cross linking is the first and only therapeutic option that has changed the natural course of keratoconus by stopping progression.[1] Cross linking is performed by using UVA at 370 nm and the photosensitizer riboflavin stiffening the collagen matrix of the cornea.[2] UV-A light with riboflavin therapy has been shown to increase corneal rigidity by 71.9% in porcine corneas and by 328.9% in human corneas.[3]

Purpose

To analyze the efficacy of Corneal Collagen Crosslinking with Riboflavin and Ultraviolet-A in progressive Keratoconus.

Materials and Methods

This study was a nonrandomized, interventional, prospective trial which included 52 eyes of 45 patients who were diagnosed to have progressive keratoconus. The study was conducted between January 2009 and June 2011 in the department of Ophthalmology, Little Flower Institute of Ophthalmology, Angamaly. An approval of the institutional ethics committee was taken prior to the beginning of the study. All the included patients provided written informed consent for the study.

Inclusion Criteria were documented progression of keratoconus by refraction (increase in cylinder by 1D or more over 1 year), or keratometry (increase in keratometry value of 1D or more over 1 year) with pachymetry more than 400 microns.[4-6] Exclusion Criteria were corneal scar, pachymetry less than 400 microns, non-progressive keratoconus, ocular pathology other than keratectasia, especially cornea guttata or other

endothelial irregularities, history of recurrent erosions, actual or intended pregnancy, not available for follow up examinations for 1 year and connective tissue disease.

A standardized form was completed for each patient documenting clinical findings including duration of symptoms, previous refraction, past treatment and predisposing ocular conditions. Pre collagen crosslinking work up included UCVA (uncorrected visual acuity), refraction and BCVA (best corrected visual acuity), slit lamp examination, keratometry, pachymetry, applanation tonometry and corneal topography. Patients using rigid contact lenses were asked not to wear them for at least 3 weeks before the preoperative examination and for 1 month after treatment.

Surgical Technique

The central 7mm of the corneal epithelium was removed using a blunt knife under topical anaesthesia with all aseptic precautions. Riboflavin 0.1% was used as photosensitizer. Riboflavin drops were applied every 5 minutes for 30 minutes. Then ultraviolet - A light of 370nm was applied for 30 minutes using 3 mW/cm2 irradiance. Even during this period riboflavin drops were applied every 5 minutes. After 30 minutes of irradiation, the ultraviolet source was removed. The eye was washed with saline. A bandage contact lens was fitted to the corneal surface until reepithelialisation.

Postoperatively patients were started on topical antibiotic, preservative free tear substitute, anti-inflammatory eye drops and oral analgesics. The patient was seen again on the first and third postoperative days. The bandage contact lens could be removed on the third postoperative day in most cases, once the epithelium healed. Further follow up visits were at 1week to rule out infection if any, 1month postoperatively and at 3, 6 and 12 months. Visual acuity, BCVA, keratometry, pachymetry and applanation tonometry ware recorded at each visit. Slit lamp examination was performed at each visit. Corneal topography was repeated at 12 months. To calculate the mean values and for comparisons, visual acuities were converted to the logMar scale.

Statistical Analysis

Based on the severity of the corneal curvature, the study patients were categorized into 2 categories:

a. category 1 - 47 - 52D in both meridians [22 eyes]
b. category 2 - more than 52 in both meridians [30 eyes]

All calculations were performed with SPSS. Variables considered were best corrected visual acuity (BCVA), maximum keratometric reading in dioptres (max K), spherical equivalent in dioptres (SE), keratometric astigmatism (KA) and intraocular pressure by applanation tonometry (AT) at the pre-procedure visit and at 3,6 and 12 months after the procedure. Descriptives presented for these variables were the mean, standard deviation (SD), 95% confidence intervals (CI) etc. Further the data was plotted using techniques like error bars and box plots. A one factor analysis of variance (ANOVA) was performed on the above variables.

Results

Of 52 eyes of 45 patients with progressive keratoconus were enrolled in this study, 69.2% were males and 30.8% were females; 28.8% were less than 18 years, 63.5% were between 18 and 30 years and 7.7% above 30 years. Forty patients (47 eyes) completed one year follow up. Five cases lost to follow up after six months. At presentation Vogt's striae could be seen in 20 eyes. Epithelial healing was completed within a mean of 3.25 + 1.4 days in all the patients. At one month all eyes had stromal haze which disappeared by 3months.

Regarding BCVA an improvement of 1 or more lines on the Snellen's chart was accepted as an improvement. Similarly a loss of one or more lines on the Snellen's chart was accepted as worsening. The other cases were considered to be stable. In all cases BCVA dropped at the one month follow up visit, but stabilized or started improving by 3 months. The initial drop could be attributed to the stromal haze following the procedure. The stromal haze cleared completely at the 3rd month follow up visit in all patients.

An improvement of BCVA was seen in 42.31% of category 1 and 26.92% of category 2. An improvement of 2 lines was seen in 9 patients and an improvement of 1 line was seen in 15. BCVA was stable in 46.15% of category 1 and 60.39% of category 2. BCVA worsened in 11.54% of category1 and 12.69% of category 2.

Figure 1 depicts the error bars showing the progression of BCVA across time. The mean preoperative BCVA in category 1 is 0.136 with a standard deviation of 0.143. At the end of one year, the mean postoperative BCVA in this category is 0.057 with a standard deviation of 0.108. A one-way ANOVA confirms that the difference in means of the value before and after the procedure at 1 year does not differ significantly (p value 0.451). The mean preoperative BCVA in category 2 is 0.414 with a standard deviation of 0.183. At the end of 1 year, the mean BCVA in this group was 0.300 with a standard deviation of 0.205. A one way ANOVA again confirms that the means of the preoperative and postoperative BCVA values does not differ significantly (p value 0.486). Hence the procedure can be claimed to preserve the visual acuity.

Changes in the maximum K reading in dioptres was also analysed over 1 year. An increase of 1D or more in the max K reading was considered to be progression of the ectasia. A decrease of 1 D or more in the max K reading was considered to be regression. The ectasia was considered to be stable in those cases where the K value continued to be within K + / - 1D. Max k reading showed regression in 32% of category 1 and 36.36% of category 2. Mean keratometric values decreased by 1.2D in category 1 and 1.02D in category 2. It was found to be stable in 61.54% of category 1 and 54.54% of category 2. Max k worsened in 6.46% of category 1 and 9.09% of category2.

Figure 2 depicts the error bars showing the change in max K reading across time. The mean preoperative max K

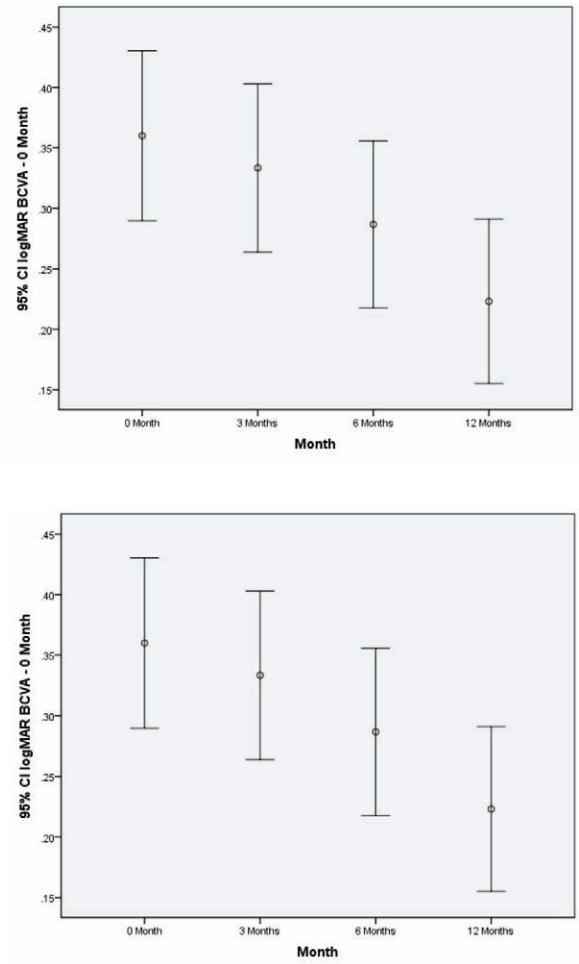

Figure 1: *Error Bar showing change in BCVA at 1 year (category 1 and 2)*

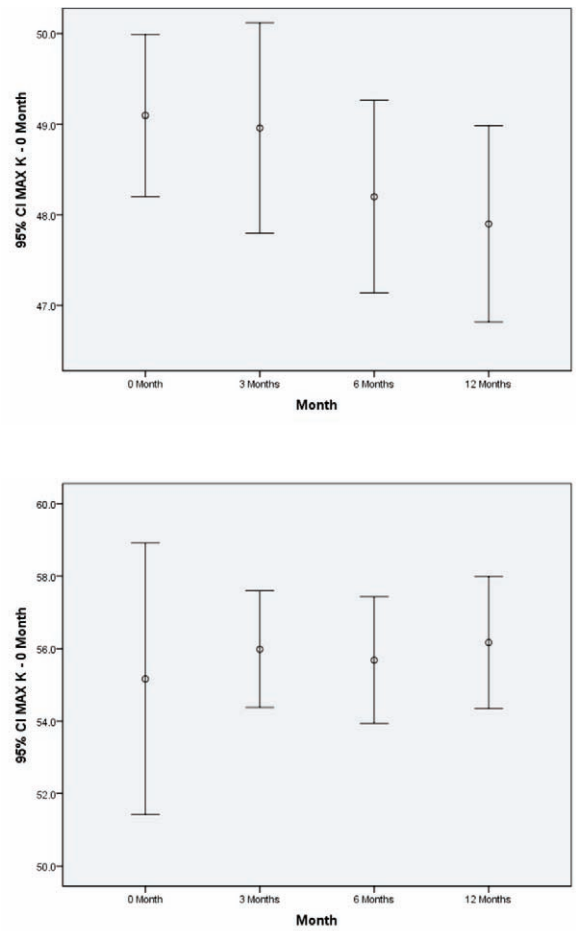

Figure 2: *Error Bar showing change in max k across time, category 1 and 2*

reading in dioptres in category 1 is 49.10 with a standard deviation of 2.019 and in category 2 is 55.16 with a SD of 10.036. At 1 year, the mean postoperative max K reading is 47.90 with a standard deviation of 2.253 in category 1 and in category 2 are 54.14 with SD of 4.506. Once again a one way ANOVA proves that the means of the max K values before and after the procedure does not differ significantly (p value 0.081, and 0.994). Hence the ectasia can be claimed to be stable.

The changes in the spherical equivalent values in dioptres following crosslinking were also analysed. An increase of 1D or more was defined to be progression of the ectasia, and a decrease of 1D or more was defined to be regression. The ectasia was considered to be stable when the spherical equivalent was within x ± 1D at the end of 1 year.

Figure 3 depicts the error bars showing the change in spherical equivalent across time. The mean preoperative spherical equivalent in category 1 was 2.495 with a SD of 2.198 and in category 2 were 5.892 with a SD of 4.177. At 1 year the mean postoperative SE was 1.913 with a SD of 1.574 in category 1 and in 2 was 4.850 with a SD of 4.224. ANOVA shows that the difference in means is not statistically significant (p value 0.115 and 0.057)

Discussion

This study has shown that collagen-crosslinking appears to be effective in stopping the progression of keratoconus quasi "freezing" the cornea. This effect is corroborated by the following data of the study. Post operative regression in the max 'k' reading was seen in 32% of the treated eyes in the mild to moderate category(category I) and 36.36% of the treated eyes in the advanced – severe category(category2). In another 61.54% of the treated eyes in category I and in 54.54% of treated eyes in category II the max K reading was found to be stable at one year, according to the definition accepted in the study.

Similarly 42.31% of the treated eyes in category I and 26.92% of the treated eyes in category II showed improvement of BCVA at the end of one year and 46.15% of the treated eyes in category I and 60.39 % of the treated eyes in category II showed BCVA to be stable at the end of one

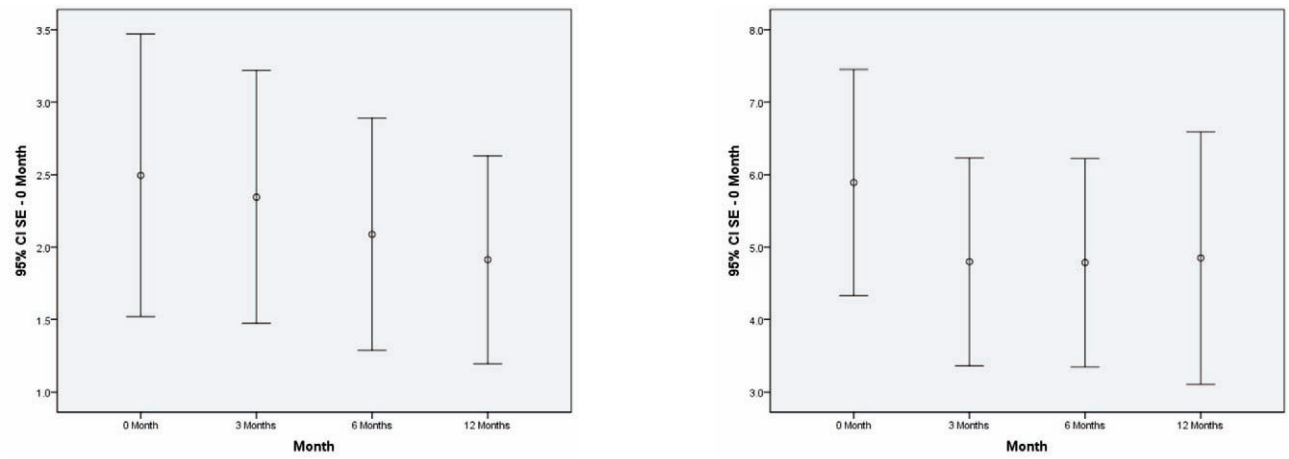

Figure 3: *Error Bars showing change in Spherical Equivalent across time in category 1 and 2*

year.This again shows that the ectasia has not progressed after cross-linking. Statistically significant 'p' values could not be derived for the improvement observed in BCVA and max K reading because of the small sample size and relatively high confidence intervals.

The mean pre operative and post operative spherical equivalents in both the categories also did not differ in a statistically significant manner (p 0.115 and 0.057).

Thus our study proves that the progression of the ectasia is arrested in the treated eyes following cross linking and that this effect is maintained up to one year. This finding is in accordance with the first clinical pilot study on crosslinking for keratoconus by Wollensak et al.[1] They reported that cross linking had a favourable effect on all treated eyes. There was also a slight reversal and flattening of keratoconus by 2D in 72% of the treated eyes. In our study, a regression of the disease was obtained in 68.36% (both category 1 and 2 together) with a reduction of mean K value by 1.8D in category 1 and 1.02D in category 2. BCVA improved slightly in 68% of the patients in the Wollensak study and in 69.23% of the patients in our study group (both category 1 and category 2 together). Hence we endorse the results of the pilot study by Wollensak et al [1] in our case series.

As already said, in our study the mean k decreased by 1.8D in category 1 and by 1.02D in category 2. Hence it is seen that though the ectasia is stabilized in both the groups, the regression is more prominent in eyes with mild-moderate disease.

The findings of Wollensak et al were further confirmed by Caporossi et al[7] who showed a regression of K max by 1.9D in 100% of his study group in 2006. He attributed it to a more symmetrical post operative shape of the cornea. The reduction of the keratoconus indices goes indeed along with a tendency towards a more regular shape of the cornea, which may explain the improvement in BCVA. Correlation analysis of BCVA and the keratoconus indices and a longer follow up may prove whether it is the more regular cornea that provides better vision.

Side effects and complications observed in our study were post operative pain until epithelialisation, photosensitivity, stromal haze and fluctuating vision up to three months. In refractive surgery, a complication is defined as a loss in BCVA of 2 or more Snellen lines 8 at an appropriate time after surgery (6m, 1yr). A refractive surgical procedure is considered safe if this complication rate is lower than 5%.[9] In our study, 11.54% of category 1 and 12.69% of category 2 showed a drop of one or more lines in BCVA at 1 year. But considering the above definition, a loss of 2 or more Snellen lines was seen only in 5.2% of category 1 and 6.8% of category 2. Serious complications like lens opacities, retinal damage, infectious keratitis, stem cell damage and endothelial decompensation were not observed in our study. This finding goes with the observation of Jasmeet et al[10] Hence the procedure can be considered to be relatively safe.

The limitations of our study include the small sample size, relatively high 95% confidence intervals for the variables considered, follow up period of only one year, lack of documentation of endothelial cell density before and after the procedure and the fact that the visual rehabilitation following the procedure was not included in the perspective of the study.

In summary cross linking appears to be a safe treatment for arresting the progression of keratoconus. Considering the very low costs and simplicity of the method, it is very suitable for developing countries where access to contact lenses and availability of donor tissue for keratoplasty is a problem.

Financial & competing interest disclosure

The authors do not have any competing interests in any product / procedure mentioned in this study. The authors do not have any financial interests in any product / procedure mentioned in this study

References

1. Wollensak G, Spoerl E, Seiler T. Riboflavin/ ultraviolet – A induced cross linking for the treatment of keratoconus. *Am. J Ophthalmol* 2003; 135:62–7.
2. Wollensak G. Cross linking treatment of progressive keratoconus: New hope. *Curr Opin ophthalmol* 2006; 17:356 – 60.
3. Marcus Kohlhaas, Eberhard Spoerl. Biomechanical evidence of crosslinks in corneas after C3R. JCRS 2006; 32:279-83.
4. Raiskup-Wolf F, Hoyer A, Spoerl E, Pillunat LE. Collagen crosslinking with riboflavin and ultraviolet-A light in keratoconus: long-term results. *J Cataract Refract Surg* 2008 ; 34: 796-801.
5. Wittig-Silva, C; Whiting M, Lamoureux E, Lindsay RG, Sullivan LJ, Snibson GR. A Randomized Controlled Trial of Corneal Collagen Cross-linking in Progressive Keratoconus: Preliminary Results. *Journal of Refractive Surgery*. 2008: S720-5.
6. Hersh PS, Greenstein SA, Fry KL. Corneal collagen crosslinking for keratoconus and corneal ectasia: One-year results. *J Cataract Refract Surgery* 2011 ;149-160.
7. Caporossi A, Baiocchi S, Mazzotta C, et al. Parasurgical therapy for keratoconus by riboflavin – ultraviolet type A rays induced crosslinking of corneal collagen. *J. Cataract Refract Surg* 2006; 32:837-45.
8. U.S. Food and Drug Administration. Center for Devices and Radiological Health. Checklist of information usually submitted in an investigational device exemptions application for refractive surgery. www.fda.gov/cdrh/ode/2093.html.
9. Kanellopoulos AJ, Binder PS. Crosslinking with sequential topography guided PRK: a temporizing alternative for penetrating keratoplasty in keratoconus. *Cornea* 2007; 26:891-5
10. Jasmeet S. Dhaliwal,et al. Corneal collagen cross linking: A confocal, electron and light microscopy study of eye bank corneas. *Cornea* 2009; 28:62-7.

Announcement

Postgraduates may send in their thesis work as **ORIGINAL ARTICLES** to the **EDITOR–IN–CHIEF**, Delhi Journal of Ophthalmology. Please specify that the submission is to be entered into the **YOUNG OPHTHALMOLOGISTS** section for consideration for best paper award. Please refer to the **INFORMATION FOR AUTHORS** section for further details.

Please write to ***editordjo2013@gmail.com*** for any clarifications regarding submissions to Delhi Journal of Ophthalmology.

Dr **M.VANATHI** MD
Editor-in-chief
Delhi Journal of Ophthalmology